

**Clinical presentation and predictive criteria for preoperative diagnosis of Primary ovarian lymphoma**Heba G.M. Mahmoud<sup>1</sup>, Marwa Nabil<sup>2</sup>, Eman. D. El Desouky<sup>3</sup>, Eman. N. Khorshed<sup>4</sup><sup>1</sup>Department of Surgery, National Cancer Institute, Cairo University, Kasr El -Aini Street, Fom El Khalig, PO Box 11796 Cairo, Egypt.<sup>2</sup>Department of medical oncology, National Cancer Institute, Cairo university, Kasr El -Aini Street, Fom El Khalig, PO Box 11796 Cairo, Egypt.<sup>3</sup>Department of Biostatistics and Cancer Epidemiology, National Cancer Institute, Cairo University, Cairo university, Kasr El -Aini Street, Fom El Khalig, PO Box 11796 Cairo, Egypt.<sup>4</sup>Department of Pathology, National Cancer Institute, Cairo University, Kasr El -Aini Street, Fom El Khalig, PO Box 11796 Cairo, Egypt.[hebasurg@yahoo.com](mailto:hebasurg@yahoo.com)

**Abstract: Objective:** To identify key clinical parameters which can guide preoperative clinical diagnosis of primary ovarian lymphoma, precluding aggressive surgery, deferment of decisive treatment, and infertility? **Patients and Methods:** A retrospective chart review of all patients diagnosed with primary ovarian lymphoma at the National Cancer Institute, Cairo - Egypt, during a 5-year period from 2008-2013 was designed and retrieved. Clinical data, imaging, pathological diagnosis, operative findings, and outcomes were gathered, with specific focusing on symptoms, duration of illness, and propensity of B symptoms, staging, imaging data, intraoperative and gross pathology descriptions of the ovaries, in addition to patient outcomes. **Results:** Primary ovarian lymphoma was diagnosed in 11 patients during the time period 2008-2013. Majority of the patients (81.8%) presented clinically with a picture mimicking epithelial ovarian tumors but they were relatively younger than patients with EOT at diagnosis (age range 14-57 years). Patients presented with an acute abdomen in (27.2 %) of cases and an open surgical biopsy was done. The diagnosis of primary ovarian lymphoma was based on postoperative pathology in all cases. Patients were treated with chemotherapy after cytoreductive surgery with estimated 91% overall survival. **Conclusions:** We present the clinical criteria and outcome of eleven cases of primary ovarian lymphoma managed in the National Cancer Institute, a major tertiary care center in Egypt. Recognized cases shared the criteria of young age, rapid disease progression, bilateral ovarian involvement, regional lymph node metastasis, positive B symptoms, in addition to typical CT, and intraoperative findings which are possible predictors of higher disease probability. Proper diagnosis by surgical biopsy followed by chemotherapy improves the outcome especially in young age. [Heba G. M. Mahmoud, Marwa Nabil, Eman. D. El Desouky, Eman. N. Khorshed. **Clinical presentation and predictive criteria for preoperative diagnosis of Primary ovarian lymphoma.** *Cancer Biology* 2017;7(1):39-48]. ISSN: 2150-1041 (print); ISSN: 2150-105X (online). <http://www.cancerbio.net>. 6. doi:[10.7537/marscbj070117.06](https://doi.org/10.7537/marscbj070117.06).

**Key words:** Primary ovarian lymphoma, preoperative diagnosis, key criteria, outcome.**Abbreviations:** Non-Hodgkin's lymphoma (NHL) Diffuse large B-cell lymphoma (DLBCL)**1. Introduction**

Primary ovarian lymphoma is a very rare disease accounting for only 0.5% of all Non Hodgkin Lymphoma (NHL) and 1.5% of all ovarian neoplasm (1). Ovarian involvement with lymphoma can be either primary or secondary to generalized systemic lymphomatous involvement in 7% to 26% of cases (2).

Most of the published literature concerning primary ovarian lymphoma discussed either small case series or case reports(1). To the best of our knowledge, the diagnosis of primary ovarian lymphoma in most of these published series was based on postoperative pathological examination following aggressive surgery (3-5).

Although previous publications tried to emphasize typical diagnostic criteria based on

imaging patterns, and intraoperative findings(6), common clinical presentations and lab results were not highlighted in order to identify the common criteria that can guide the preoperative diagnosis of primary ovarian lymphoma. The reported histological subtypes of NHL that are known to involve the ovary primarily are presented in Table (1).

The most common imaging patterns of ovarian NHL include bilateral and homogeneous hypo dense ovarian masses exceeding 5 cm in diameter, without ascites, associated with concurrent adenopathy and/or hepatosplenomegaly, and compression of the urinary tract(7)(1, 8).

Prognosis of NHL is dependent upon the prompt institution of appropriate therapy which is chemotherapy and the role of surgery is only limited to initial diagnostic biopsy. Patients with extra nodal

disease, therefore, tend to have worse outcome, secondary to the time delay and confusion in diagnosis and management(9). Establishing a precise diagnosis of ovarian NHL is critical since treatment is fundamentally different from other ovarian masses.

Avoiding aggressive surgery that affects patients' fertility and quality of life especially in young patients is of particular importance.

In this study, we are trying to identify predictive clinical parameters that serve as red flags when encountering an ovarian mass, alerting respective clinicians to the likelihood of primary ovarian lymphoma. The aim is to avoid delays in the diagnosis and management that negatively impact patient outcomes and at the same time to minimize unnecessary radical surgery, with its attendant morbidity.

## 2 Patients and Methods

Anonyms data handling was done and the informed consent was waived due to the retrospective nature of the study. All patients with primary ovarian involvement diagnosed as NHL at the National Cancer Institute, Cairo University, during the time period from 2008 till the end of 2013 were eligible for this retrospective study. The final diagnosis was established by pathological examination and immunohistochemical confirmation using certain antibodies (LCA, CD20, CD10 and CD3).

Medical files of the patients were retrieved and relevant collected data included patient demographics, clinical characteristics at the initial presentation, symptoms associated with the ovarian disease, date of diagnosis, radiological and laboratory investigations, gross pathology, surgical interventions, chemotherapeutic regimen, survival, and last date of follow-up.

Primary ovarian involvement was established when the ovary was the only and the dominant site of affection irrespective of associated regional lymph node status.

Contiguous (concomitant) involvement of other organs such as gynecologic tract was allowed if the ovarian lesion was the presenting site and bone marrow and peripheral blood have not contained any abnormal cells, and if extra-ovarian disease appeared later (Time lapse of a few months between the appearance of ovarian and extra-ovarian lesions). These criteria were defined before by Fox et al(10).

Every case was studied carefully to identify the clue points to build up the suggested algorithm. The key differences were compared to primary epithelial ovarian tumor presentation based on the literature.

### Statistical analysis:

Data management and statistical analysis were performed using Statistical Package for Social

Sciences (SPSS) v.21. Numerical data were summarized using means and standard deviations or medians and ranges. Categorical data were summarized as percentages. Kaplan and Meier's procedure was used to estimate the overall survival rates. Overall survival rates were calculated from the date of diagnosis to date of death from any cause. Living patients or patients lost to follow-up were censored on last known alive date.

## 3. Results

### Patients 'Characteristics:

The total number of lymphoma patients presented to the National Cancer Institute, Cairo – Egypt, during the period from 2008 to 2013 were 4500 cases. Only eleven cases of them (0.0024%) involved the ovaries primarily. Patient characteristics and clinical presentations of the reported cases are shown in table (2). The applied management of these patients is shown in table (3). The mean age was 31.3 years (range: 14 to 57 years). Initial presentation with ascites was found in three patients (27.2 %), while another three patients (27.2 %) presented clinically with acute abdomen mimicking appendicitis.

B-symptoms were documented in only two cases (18.2 %) and not sought in four cases (36.4 %), three of them were younger than 35 years of age.

The most common pathological subtype was diffuse large B-cell NHL(45.5%) followed by Burkitt lymphoma in 4 cases

### Patients' management and outcome:

Management protocols and details of studied patients are shown in the tables (3) and (4). LDH was very high in three cases preoperatively while CA-125 was ordered in five patients. Preoperative CT was done in one case; she was 24 years old with the longer duration of symptoms of around 5 months, she was managed by total abdominal hysterectomy and bilateral salpingo-oophorectomy. The size of the masses exceeded 5cm in all cases, mean tumor size was 12.5 cm. In about half of the cases(45.5%), the tumor was grayish pink in color and completely replacing the ovaries bilaterally. Three patients underwent biopsy and/ or ovariectomy for pathological confirmation; they were younger than 30 years of age. One of these cases was nulliparous and presented to the emergency unit with acute abdomen and an ovarian mass, she did not show B-symptoms but she had very high LDH. Three patients showed few subcentimetric regional para-aortic and pelvic nodes radiologically. Whole body screening for peripheral nodes and for hepatosplenomegaly by clinical examination was free.

After a pathological diagnosis of ovarian lymphoma based on immunophenotyping, all of our

patients received chemotherapy regimens in the form 6 cycles of cyclophosphamide, daunorubicin, and Oncovin. One patient received endoxane/prednisone (CHOP regimen), although management of diffuse large B cell NHL is by RCHOP regimen but rituximab was not available at that time at our institute and now it is given on routine bas.

The overall survival rate of the patients is shown in figure(1) with the mean follow-up time was 37 months with minimum of 2 months up to maximally 60 months. One patient died after 6 months from the diagnosis; she was 14 years and received 6 cycles of CHOP. One patient lost follow up early at 2 months after surgery.

**Table (1): Socio-demographic Characteristics and clinical presentation of NHL patients with disease involving the ovary (n = 11)**

Factors		Number	Percent
<b>Age</b>	Mean $\pm$ SD	31.3 $\pm$ 14.3	
	Range	14-57	
	<40	8	
	40	1	
	>40	2	
<b>Marital status</b>	Single	3	27.3
	Married	8	72.7
<b>Number of children</b>	Median (range)	2(0-6)	
<b>Menopausal status</b>	Premenopausal	10	90.9
<b>Occupation</b>	HW	8	72.7
	Student	3	27.3
<b>Presenting symptoms<sup>a</sup></b>	Abdominal pain	3	27.3
	Ascites	3	27.3
	Pelvi-abdominal mass	9	81.8
<b>Duration of symptoms</b>	Acute pain	3	27.3
	$\geq$ 1 month	8	72.7
<b>B-symptoms</b>	Present in	2	18.2
	Not asked	4	36.4
	Not present	5	45.4
	No masses	1	9.1
<b>laterality</b>	Bilateral	5	45.5
	Right	5	45.5
<b>Pathological types</b>	DLBCL	6	54.5
	Burkitt	3	27.3
	Lymphoblastic lymphoma	2	18.2

SD: standard deviation, HW: house Wife, a: patients may present with multiple symptoms, DLBCL: diffuse large b cell

**Table (2): Management of NHL patients with disease involving the ovary (n = 11)**

Factors		Number	Percent
<b>LDH</b>	High	3	27.3
	Not done	8	72.7
<b>CA125</b>	High	5	45.5
	Not done	6	54.5
<b>Imaging study</b>	<b>Pelvic CT</b>	1	9.1
	Pelvic Ultrasound	10	90.9
<b>Ascitic tap</b>	Positive	1	9.1
	Negative	3	27.3
	Not done	7	63.6
<b>Mass size (cm)</b>	Median (range)	12.5(7-18)	
<b>Surgery</b>	Biopsy	1	9.1
	BSO	3	27.3
	Rt. Oophorectomy	2	18.2
	TAH/BSO	5	45.5
<b>Omentectomy</b>	Performed	6	54.5
	Not performed	5	45.5
<b>Omental histology</b>	Positive	2	
<b>Other organ resection</b>	Negative	4	
	None	5	45.5
	Appendectomy	1	9.1
	Ileal resection	2	18.2
	Para-aortic LN biopsy	1	9.1
	Pelvic LN sampling	1	9.1
	Small intestine mass	1	9.1
<b>Chemotherapy regimen</b>	CHOP/6	10	90.9
	COP	1	9.1

BSO: bilateral salpingo-oophorectomy, TAH: total abdominal hysterectomy, LN: lymph node, chop: cyclophosphamide, daunorubicin, Oncovin, prednisone.

**Table (3): Details of 11 cases of primary NHL in this study**

Patient number	Age (years)	presentation	laterality	Surgery	Histologic type	Ann Arbor Staging post operative	Preoperative Fig staging	Chemotherapy regimen	Follow Up duration (months)	Outcome
1	14	Pelviabdominalmass,pallor	bilateral	BSO/TAH/small intestinal resection/omentectomy	Burkitt	IEB	3a	COP	18 m	Alive,disease free
2	14	Pelviabdominalmass,abdominal pain	right	Biopsy	NHL Btype,diffuse large cell, DLBCL	IE	2c	CHOP	30m	Alive,disease free
3	17	Pelviabdominalmass,rt iliac fossa swelling	bilateral	BSO/TAH/omentectomy	plasmoblastic myeloma with plasmablastic lymphoma transformation	IE	1b	CHOP	42m	Alive,disease free
4	24	Pelviabdominalmass,ascites,abdominalpain,vomiting,bilateral lower limb edema	bilateral	BSO/ileal resection/omentectomy	Burkitt	IE	3c	CHOP	65m	Alive,disease free
5	28	Pelviabdominalmass,right iliac fossa mass	bilateral	BSO/TAH & pelvic lymph node sampling/omentectomy	NHL, DLBCL	IE	3c	CHOP	72m	Alive,disease free
6	30	Abdominal pain		RT ovariectomy&appendectomy	NHL, DLBCL	IE	3c	CHOP	48m	Alive,disease free
7	31	Pelviabdominal mass	Right	BSO & paraaortic lymph node biopsy	NHL, DLBCL	IE	3c	CHOP	36m	dead
8	39	Pelviabdominalmass,change in bowel habits	right	BSO/TAH/omentectomy	NHL(mixed small & large)	IEB	3c	CHOP	0m	Alive,disease free
9	40	Ascites and abdominal distension	Right	ltovariectomy	NHL (small cell)	IE	1a	CHOP	36m	Alive,disease free
10	51	Pelviabdominal mass,	Right	BSO/TAH/omentectomy	NHL,Btype,large cell, DLBCL	IE	1b	CHOP	Nk	Lost follow up
11	57	Pelviabdominal mass,ascites,right iliac fossa swelling	bilateral	BSO	NHL(pre B)	IB		CHOP	60m	alive

BSO: bilateralsalpingo-oophorectomy, TAH: total abdominal hysterectomy, RT: right, NHL: nonhodgkinlymphoma, nk: notknown, DLBCL: diffuse large b cell, Chop: cyclophosphamide, daunorubicin, Oncovin, prednisone

**Table (4): Critical clinical points that are easily missed during management of young patients with pelviabdominal mass involving the ovary.**

Steps	Criteria	Lymphoma expected when	
1	Age of patient	Young (pediatric population or < 40 yrs.)	
2	Clinical presentation	Acute presentation	Acute abdomen, short duration of symptoms around 1 month
		Duration of symptoms	Rapid
		Disease progression	
		B-symptoms (positive)	-Unexplained loss of more than 10% of bodyweight in the preceding six months before diagnosis -Unexplained fever with temperature above 38°C -Drenching night sweats
3	Complete physical examination and examination of peripheral lymph nodes	Hepatomegaly Splenomegaly Peripheral lymph nodes	
4	laboratory investigations	CBC	Further investigation for any abnormality (anemia or lymphocytosis)
		Liver function test	
		LDH	If high bone marrow aspiration and biopsy should be done
		CA125 Tumor marker panel for germ cell tumors (BHCG, alpha fetoprotein)	Not very high Negative
5	Diagnostic imaging	Preoperative CT abdomen and pelvis	The typical imaging criteria cited by ferrozi et al (6) in primary ovarian lymphoma
		Trans vaginal U/S Abdominal Ultrasound MRI	Non specific: hypoechoic mildly vascularized tumor hypointense large solid bilateral ovarian masses on T1 weighted and of intermediate to high signal intensity on T2 weighted images.
6	Intraoperative	Frozen section	low sensitivity, good with proper expertise
		Intraoperative findings	bilateral presentation of equal masses having the shape of the ovaries, grayish in color confined within the ovarian capsule and the presence of lymph nodes Ascites /peritoneal implants
		Biopsy	-LN if present
			-Unilateral ovariectomy

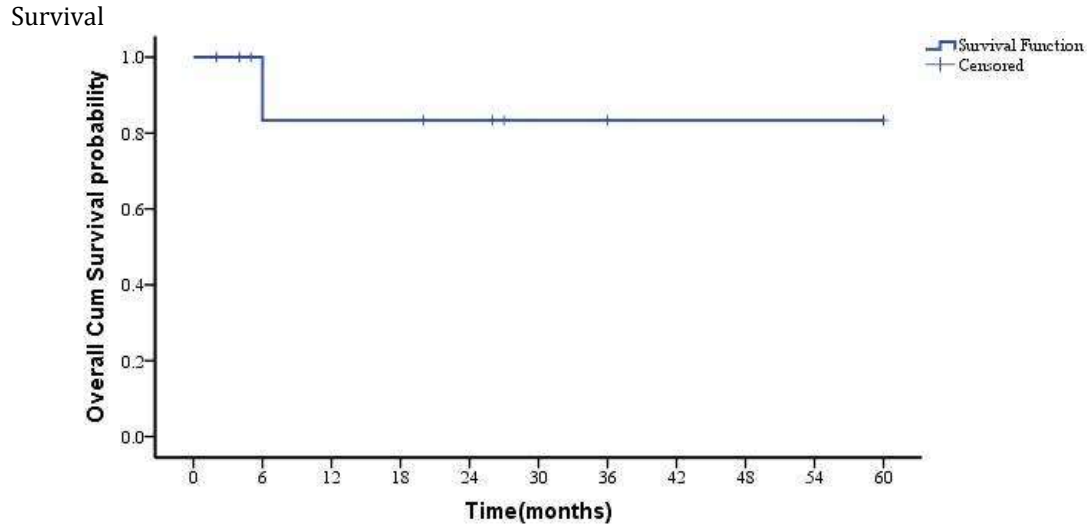


Figure (1): overall survival

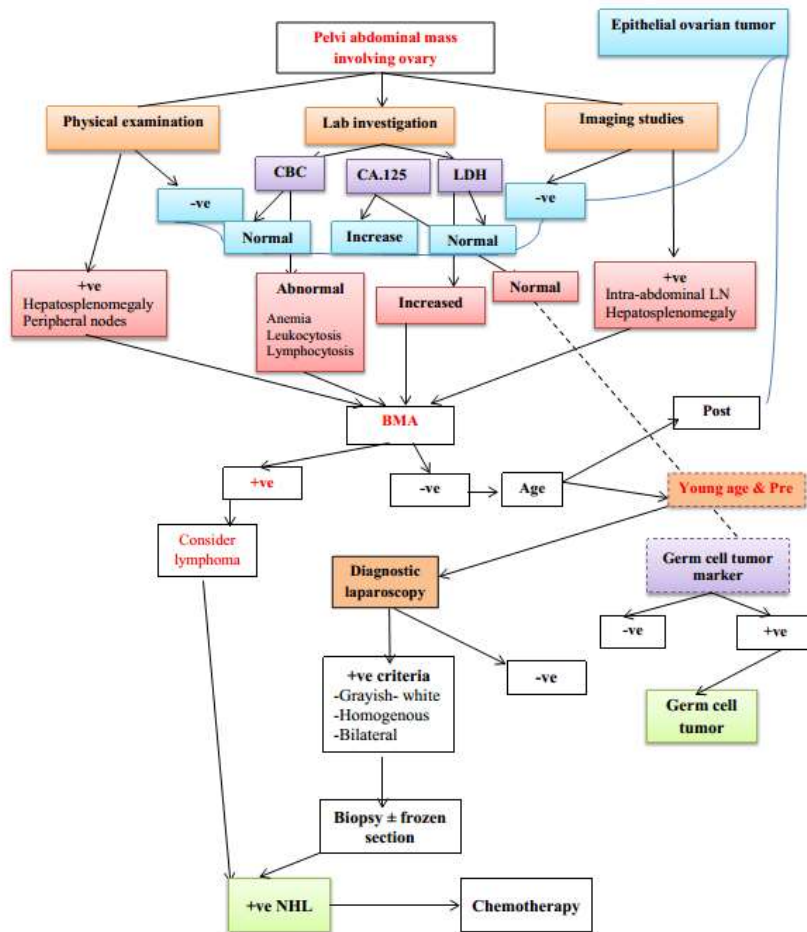


Figure (2) in supplementary material: Algorithm for the preoperative diagnosis of primary ovarian lymphoma

#### 4. Discussion

Primary ovarian lymphoma tends to be misdiagnosed as ovarian epithelial malignancy because it is a very rare disease, representing (0.0024%) of all Lymphoma cases presenting to our hospital during the period from 2008 to 2013.

##### Patients Characteristics and clinical presentation:

Young women have a higher probability of the diagnosis of a primary ovarian lymphoma rather than an advanced ovarian epithelial tumor. In a large case series of primary ovarian lymphoma the median age at diagnosis was 43 years with a range from 18 -66 years old. In a review article and a case report published on primary ovarian lymphoma, the author reported that most of the patients are young, with a median age of 42-47 years(1).

This case series validates the suggestion that primary ovarian lymphoma tends to affect premenopausal patients (90.9% of this case series), that could be explained by the more active blood flow to the ovary during the premenopausal period, which may increase the presence and dissemination of lymphoma cells. The reason for this finding also may be related to the most common histological subtypes of NHL which presents at younger age. Although DLBCL is common in the fourth and fifth decades of life, Burkitt's lymphoma is more common in younger patients(11). Two patients diagnosed with Burkitt's lymphoma in this study were teenagers (14 years old) in agreement with the literature reporting that one-half of ovarian malignancies in childhood are Burkitt lymphoma(12).

The short duration and the rapid progression of the presenting clinical symptoms must be taken into consideration since 27.3% of our cases presented acutely in an emergency setting while 83.7% had symptoms for equal or more than one month duration in contrast to epithelial ovarian tumors which are usually presenting with a chronic course and a long duration of non-specific symptoms like constipation, ascites and dyspepsia (13). One case report published reported the presentation of an ovarian lymphoma acutely in the form of peritonitis (14).

The diagnosis of lymphoma limited to the ovary is usually difficult and challenging especially that the main presentation of most of the cases in our series is that of a locally advanced pelviabdominal mass (81.1 %) mimicking epithelial ovarian neoplasm a. In a published case series on primary ovarian lymphoma, the pelviabdominal mass presentation was reported to be found in 18.7 % of the cases (11).

Patients with primary gynecologic lymphoma usually do not have B symptoms(15). Positive B symptoms were only found in three cases in this current study.

The presence of bilateral homogeneous ovarian involvement seems to be one of the common features reported for primary ovarian lymphoma (16). This finding was present in 45.5% of our included cases, it has been reported to be a useful finding for the diagnosis(16). On the other hand, the bilaterality of the ovarian masses can point towards a more advanced stage if epithelial ovarian tumors are considered as a diagnosis.

Preoperative Clinical and radiological screening of all the body lymph node groups, hepatomegaly or splenomegaly is essential for the diagnosis of primary versus secondary ovarian lymphoma and can help in the differential diagnosis.

DLBCL in the ovary is the most common type, followed by Burkitt's lymphoma, Follicular lymphoma and small lymphocytic lymphoma. The latter occur, but more commonly in older women. In this study the most common pathological subtype was also DLBCL followed by Burkett lymphoma.

##### Diagnosis and management:

The main imaging modality used in this study preoperatively was the abdominal and pelvic U/S (done in 90.9% of the cases). Computed tomography of the abdomen and pelvis was only done in one patient. This contributed to missing important criteria that may have been present on CT.

Computed tomography in ovarian lymphoma was studied by Ferrozi et al and proved to be specific with the picture of hypodense lesions with mild contrast enhancement. In the absence of ascites and the presence of bilateral homogenous ovarian tumors, the diagnosis of ovarian lymphoma could be considered(6).

Ovarian lymphomas display nonspecific features on ultrasonography, presenting as mildly vascularized homogenous hypo-echoic lesions(7).

MRI appears to be the best modality for visualization of a hypovascular mass and preservation of anatomic planes. Ovarian lymphoma typically displays a hypointense large solid bilateral ovarian masses on T1 weighted and of intermediate to high signal intensity on T2 weighted images(17). Solid peritoneal implants, as well as ascites, could be seen as in epithelial ovarian tumors making the diagnosis of ovarian lymphoma difficult(12).

Estimation of serum level of LDH was ordered in only 27.3% preoperatively and was high however it was not ordered in the other eight cases reflecting the rarity of the disease and the lack of diagnostic approach for such cases.

Serum level of CA-125 was ordered in 45.5% of cases with a high-level result. This resulted in misleading the diagnosis towards an advanced epithelial ovarian tumor rather than a primary

lymphoma guiding the surgeon towards a radical type of cytoreductive surgery.

Nearly half the cases (45.5%) showed the same intraoperative gross appearance as the tumor was grayish pink in color with a bilateral and homogenous involvement of both ovaries. The tumor was completely replacing the ovaries and taking their shape but all still inside an intact capsule. This picture is different from that of epithelial ovarian tumors which are usually disseminated inside the peritoneal cavity and not totally confined to the ovaries in the advanced stages.

Although ascites were present in 27.3% of the cases, this fact was contributing to the misdiagnosis of the locally advanced epithelial ovarian tumor rather than ovarian lymphoma. Ascites represents an advanced stage in epithelial ovarian tumors however the presence of ascites in primary ovarian lymphoma is not a common finding as reported in the few case series and review of literature published.

Lymphomas, in general, are known to cause encasement rather than infiltration or disruption of adjacent organs. Ferrozzi et al(7) studied five cases of ovarian lymphoma using MRI radiological findings and noted a predominant non-infiltrative pattern of growth(14).

Due to the lack of precise diagnostic criteria and the rarity of the disease, most of our patients (72.8%) were exposed to radical surgery rather than a biopsy aiming at no residual tumor afterward.

Only three of the patients had a surgical biopsy reflecting the lack of specific criteria for the diagnosis of primary lymphoma of the ovary preoperatively. In many patients in our series, the criteria for the diagnosis of primary ovarian lymphoma were not obvious to the primary surgeon and many positive criteria were overlooked being an uncommon differential diagnosis.

The radical type of surgery that our patients had, reflects the limitation of the frozen section analysis reported in the literature when done on ovarian tumors(18).

An equivocal result of a frozen section in the context of a diagnosis of epithelial ovarian tumor forces the surgeon to perform the surgical staging appropriate to the case.

In our center, the frozen section is not always available too, explaining the radicality of the surgery done.

In the literature, the maximal surgical excision of the tumor does not seem to be associated with a better prognosis(1). On the other hand, the combination of biopsies and well-adapted chemotherapy seems to be the pertinent choice in the management of these patients.

In a study published by Jina et al (11), the role of radical surgery in primary ovarian lymphoma could not be established like in other types of ovarian tumors especially the epithelial type. He reported that three of his patients relapsed despite radical surgery for ovarian lymphoma(11).

The frozen section analysis in the ovarian neoplasms has a reported overall accuracy from 86 to 97%(19). Nevertheless, it has its limitations especially in cases of rare or uncommon ovarian neoplasms (19). Also the availability of this tool in low resource centers with the proper expertise lacking making it an unreliable tool to depend on for the diagnosis of ovarian lymphoma.

The available data support a multiple therapies essentially based on a chemotherapy regimen appropriate to the specific histological type of each lymphoma type (17). Unlike the situation with the more common epithelial ovarian malignancies where radical surgery is essential.

### Survival Analysis

It has been reported that primary ovarian lymphoma in children and adolescents usually has aggressive behavior as the tumor rapidly and diffusely progresses, whereas in adults there could be an indolent or aggressive type of lymphoma(12).

In the literature, the outcome of patients with primary ovarian non-Hodgkin's lymphoma (NHL) is controversial. A retrospective analysis experience with adults seen at the University Of Texas M. D. Anderson Cancer Center from 1974 to 1993 reported that the complete remission rate and DFS of patients with ovarian NHL treated with appropriate chemotherapy appear to be similar to that of patients with other nodal NHLs(20).

Other authors reported that primary ovarian lymphoma show poor outcome with a range from 0% to 36% expected to survive for less than three years(3).

Although the number of patients with ovarian involvement was small in this study, the assessment of their clinical features reflected organ-specific characteristics:

In the context of a young patient (pediatric population or 40 years or less ) presenting with a huge or large pelvic abdominal mass of short duration, the diagnosis of ovarian lymphoma should be considered after ruling out the most common ovarian tumors in this age group like germ cell or sex cord stromal tumors using specific markers and investigations.

When presenting in the clinical setting of a relatively young premenopausal patient presenting with a pelviabdominal mass involving the ovary, every effort should be done by the surgeon to diagnose it by taking into consideration the following



critical clinical points stated in the table(5), that are easily missed and should be kept in mind.

These criteria together are crucial and essential to reach the correct diagnosis preoperatively or at the worst intraoperatively, thus limiting the role of surgery to a biopsy.

The limitation of this study is that it was done on a very small number of cases, the rarity of the disease justifies the small number; however the study was done in a tertiary cancer center of referral reflecting the real incidence of the disease.

Most of the articles reported in the literature on primary ovarian lymphoma were in the form of case reports and few case series with very small number of patients comparable to our study(4).

The key clinical points and the algorithm proposed in this case series are based on our observations of the common features in the cases as well as on the data from the small series available and the known differences between primary ovarian lymphoma and the epithelial ovarian tumors. Further studies with large numbers should be done which can validate the proposed algorithm for the diagnosis of primary ovarian lymphoma preoperatively.

### Conclusion

In the presence of disease specific characteristics listed in this study, the surgeon and the pathologist should consider the diagnosis of a primary ovarian lymphoma. The prospective diagnosis of primary ovarian lymphoma enables immediate chemotherapy or radiation therapy and avoids unnecessary surgery which delays treatment.

The use of the suggested pattern and algorithm to manage patients with ovarian masses may help preoperative or, at least, intraoperative suspicion of such a rare disease. In case of suspicion of primary ovarian lymphoma, a diagnostic laparoscopy or a mini-laparotomy would be warranted.

The early diagnosis enables the detection of an early disease and the preservation of fertility of young women by avoiding the use of radiotherapy. There were reports on the successful completion of pregnancy and live birth after chemotherapy(5). Radical surgery can be avoided while preserving the quality of life of these patients, especially young premenopausal women.

### Conflict of interest:

The authors report no conflict of interest.”

### Financial support:

No financial support have been obtained.

### Corresponding Author

Hebatallah Gamal El Din Mohamed Mahmoud

Department of surgery, National Cancer Institute, Cairo university, Kasr El -Aini Street, Foum El Khalig, PO Box 11796 Cairo, Egypt.

E-mail: [hebasurg@yahoo.com](mailto:hebasurg@yahoo.com)

### References:

1. Weingertner AS, Hamid D, Roedlich MN, Baldauf JJ. Non-Hodgkin malignant lymphoma revealed by an ovarian tumor. *Gynecologic Oncology*. 2004;95(3):750-4.
2. Hu R, Miao M, Zhang R, Li Y, Li J, Zhu K, et al. Ovary involvement of diffuse large B-cell lymphoma. *Am J Case Rep*. 2012;13:96-8.
3. Senol T, Doger E, Kahramanoglu I, Geduk A, Kole E, Yucesoy I, et al. Five Cases of Non-Hodgkin B-Cell Lymphoma of the Ovary. *Case Reports in Obstetrics and Gynecology*. 2014;2014:1-5.
4. Mastilovic K, Jovanovic D, Ivkovic-Kapic T, Kopitovic S. Lymphoma ovarii case survey. *Arch Oncol*. 2009;17(1-2):27-8.
5. Islimye Taskin M, Gokgozoglu L, Kandemir B. Primary Ovarian Large B-Cell Lymphoma. *Case Reports in Obstetrics and Gynecology*. 2013;2013:1-3.
6. Crasta J, Vallikad E. Ovarian lymphoma. *Indian J Med Paediatr Oncol*. 2009;30(1):28.
7. Ferrozzi F, Catanese C, Uccelli M, Bassi P. [Ovarian lymphoma. Findings with ultrasonography, computerized tomography and magnetic resonance]. *La Radiologia medica*. 1998;95(5):493-7.
8. Ferrozzi F, Tognini G, Bova D, Zuccoli G. Non-Hodgkin Lymphomas of the Ovaries: MR Findings. *Journal of Computer Assisted Tomography*. 2000;24(3):416-20.
9. Kendrick JE, Straughn JM. Two cases of non-Hodgkin's lymphoma presenting as primary gynecologic malignancies. *Gynecologic Oncology*. 2005;98(3):490-2.
10. Fox H, Langley FA, Govan ADT, Hill AS, Bennett MH. Malignant lymphoma presenting as an ovarian tumour: a clinicopathological analysis of 34 cases. *BJOG: An International Journal of Obstetrics and Gynaecology*. 1988;95(4):386-90.
11. Yun J, Kim SJ, Won JH, Choi CW, Eom HS, Kim JS, et al. Clinical features and prognostic relevance of ovarian involvement in non-Hodgkin's lymphoma: A Consortium for Improving Survival of Lymphoma (CISL) report. *Leukemia Research*. 2010;34(9):1175-9.
12. Ferry JA. *Hematologic Neoplasms and Selected Tumor-Like Lesions Involving the Female Reproductive Organs*. Blaustein's Pathology of the Female Genital Tract: Springer Science + Business Media; 2011. p. 1137-58.

13. Vine MF, Ness RB, Calingaert B, Schildkraut JM, Berchuck A. Types and Duration of Symptoms Prior to Diagnosis of Invasive or Borderline Ovarian Tumor. *Gynecologic Oncology*. 2001;83(3):466-71.
14. Pandey S, Devanand B, John B, Singh G, Sivanandam S, Leelakrishnan V. High-grade non-Hodgkin's lymphoma of ovary presenting as peritonitis. *J Can Res Ther*. 2015;11(3):663.
15. Trenhaile TR, Killackey MA. Primary Pelvic Non-Hodgkin's Lymphoma. *Obstetrics & Gynecology*. 2001;97(5):717-20.
16. Cohn DE, Resnick KE, Eaton LA, deHart J, Zanagnolo V. Non-Hodgkin's lymphoma mimicking gynecological malignancies of the vagina and cervix: a report of four cases. *International Journal of Gynecological Cancer*. 2007;17(1):274-9.
17. Onyike I, Kirby AB, McCarthy S. Primary Gynecologic Lymphoma: Imaging Findings. *American Journal of Roentgenology*. 2013;201(4): W648-W55.
18. Shahraki A, Mohammadzadeh F, Zafarbaksh A. Intraoperative diagnosis by frozen section study would prevent unnecessary surgery in ovarian Burkitt's lymphoma. *Advanced Biomedical Research*. 2014;3(1):71.
19. Stewart CJR, Brennan BA, Koay E, Naran A, Ruba S. Value of cytology in the intraoperative assessment of ovarian tumors. *Cancer Cytopathology*. 2010;118(3):127-36.
20. Dimopoulos MA, Daliani D, Pugh W, Gershenson D, Cabanillas F, Sarris AH. Primary Ovarian Non-Hodgkin's Lymphoma: Outcome after Treatment with Combination Chemotherapy. *Gynecologic Oncology*. 1997;64(3):446-50.

3/7/2017